Knee Injuries in the Elite American Football Player: A Descriptive Pictorial Imaging and Mechanism of Injury Review

Ricardo J. Hernandez, DO, Joseph D. Lamplot, MD,† Kyle E. Hammond, MD,† Nirav B. Joshi, MD,‡ Phillip K. Wong, MD,‡ Monica Umpirrez, MD,‡ Adam Singer, MD,‡ and Felix M. Gonzalez, MD‡*

Abstract: Musculoskeletal injuries are common in American football, with an incidence ranging from approximately 10 to 35 per 1000 playing hours. Injuries occur more commonly in games than in practice. Although several studies have analyzed specific injury types in football, this review aims to describe the most common knee injuries sustained by American football players and to review the existing literature pertaining to the radiologic findings used in the diagnosis of these injuries.

Key Words: knee, professional athlete, MRI, injury

(*J Comput Assist Tomogr* 2022;00: 00–00)

PURPOSE

Musculoskeletal injuries are common in American football, with an incidence ranging from approximately 10 to 35 per 1000 playing hours.[1] Injuries occur more commonly in games than in practice.[2] Although several studies have analyzed specific injury types in football, this review aims to describe the most common knee injuries sustained by American football players and to review the existing literature pertaining to the radiologic findings used in the diagnosis of these injuries.

LIGAMENTOUS INJURIES

The knee is the most commonly injured joint in football players, with nearly 75% of these injuries occurring during games.[3] The incidence of knee sprain injuries has been shown to increase proportionally to the level of competition.[4] Feeley et al[5] reported that during preseason training camp of a National Football League (NFL) team, sprains were the most commonly sustained knee injury, with the medial collateral ligament (MCL) injured in 78% of sprains. Most MCL injuries result from a direct contact mechanism resulting in a valgus moment to the knee joint. Although ligament sprains are largely a clinical diagnosis, imaging modalities such as radiographs, ultrasound, and magnetic resonance imaging (MRI) may be obtained to confirm the diagnosis and to assess for the presence of concomitant injuries.

From the *Department of Orthopaedic Surgery, Beaumont Health System, Farmington Hills, MI; †Sports Medicine Division, Department of Orthopaedic Surgery, Emory University; and ‡Department of Radiology and Imaging Sciences, Emory School of Medicine, Atlanta, GA.
Received for publication May 12, 2021; accepted August 25, 2021.
Correspondence to: Felix M. Gonzalez, MD, Section of Musculoskeletal Imaging, Department of Radiology and Imaging Sciences, Emory University Hospital, 59 Executive Park South, 4th Floor Suite 4009, Atlanta, GA 30329 (e-mail: felix.m.gonzalez@emory.edu).
Author Contributions: All authors were involved in the research, drafting, and editing of this manuscript.
The authors declare no conflict of interest.
Copyright © 2022 Wolters Kluwer Health, Inc. All rights reserved.
DOI: 10.1097/RCT.0000000000001259

Medial Collateral Ligament

Acute superficial MCL (sMCL) injuries can be graded based on MRI appearance. Grade 1 sMCL tears are microscopic tears that manifest as subcutaneous edema and/or hemorrhage adjacent to a grossly intact ligament. Concomitant pathologies that may occur include medial compartment injury (medial meniscus, meniscocapsular junction, articular cartilage) or a patellar dislocation. Grade 2 injuries are macroscopic partial tears that appear on MRI as intrasubstance signal intensity changes with or without fluid signal changes surrounding the ligament (Fig. 1). Grade 3 injuries (Fig. 2) are complete ligament disruptions with obvious ligament discontinuity. This MRI-based grading system has been strongly correlated with instrumented varus-valgus laxity testing.[6] Grade 2 injuries may demonstrate discordance between physical examination and MRI findings.[7,8] Mirowitz and Shu[9] compared different MR sequences in the evaluation of collateral ligament injuries and found that, although all pulse sequences were similar in grading injury, collateral ligament and associated injuries were best visualized on fat-saturated T2-weighted images.

Tears of the sMCL most often occur just proximal to the joint line, but distal sMCL tears have also been reported.[10] Logan et al[11] examined 337 MRI-positive MCL tears in NFL players and found that only 5% of these injuries occurred distally. Distal sMCL tears, especially complete tears that displace superficial to the pes anserine tendons (Stener lesions, Fig. 3) have a lower likelihood of anatomic healing with nonoperative management and can result in chronic valgus instability. Tears of the distal portion of the ligament have been described as having a serpentine appearance on MRI, or a "wave sign."[12] Chronic tears of the MCL appear on MR as thickened, fibrous tissue with a paucity of edema and can also present with intrasubstance calcification referred to as a Pelligrini-Stieda lesion.

Radiographs play an important role in the diagnosis of MCL injuries. Bony avulsions are uncommon but can occur. Valgus stress radiographs can also be used to quantify ligamentous laxity or disruption. Although an increase in medial joint space gapping with valgus stress has long been categorized as mild (0–5 mm), moderate (5–10 mm), and complete (>10 mm) measured in full extension, LaPrade and colleagues[13] reported that, when compared with the contralateral uninjured knee at 20 degrees of flexion, a 3.2-mm difference of medial compartment gapping suggests a grade III sMCL tear.

Recent interest has also been brought to tears of the posterior horn of the medial meniscus at the meniscocapsular junction in patients with anterior cruciate ligament (ACL)–deficient knees, otherwise known as ramp lesions.[14] These lesions have a reported incidence as high as 40% in patients with concomitant ACL tears, as the medial meniscus plays a significant role in the prevention of anterior tibial translation in the setting of ACL deficiency.[15,16] These lesions remain underdiagnosed intraoperatively secondary to limitations in traditional arthroscopic portals limiting the visualization of posteromedial structures.[16] The importance of preoperative detection of these lesions therefore cannot be understated,

Copyright © 2022 Wolters Kluwer Health, Inc. Unauthorized reproduction of this article is prohibited.
This paper can be cited using the date of access and the unique DOI number which can be found in the footnotes.

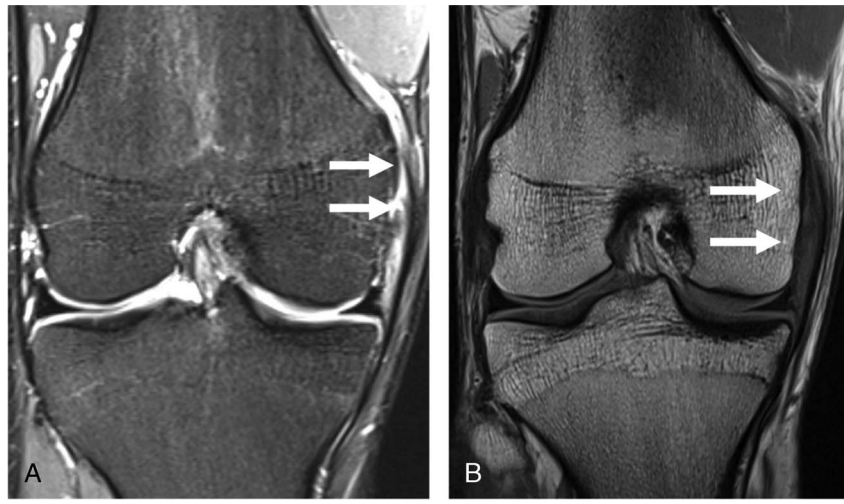

FIGURE 1. Coronal T2-weighted fat-suppressed image (A) on an athlete after a subacute valgus left knee injury demonstrates partial-thickness undersurface tearing (grade 2 sprain) of deep component of the proximal MCL. Accompanying proton density-weighted fat-nonsuppressed image (B) shows lack of ligament fiber definition.

yet the sensitivity of MRI remains less than 50%.[17] A high index of suspicion is therefore warranted when interpreting MRI results in patients with acute and chronic ACL tears. The first finding suggestive of a ramp lesion is a high signal intensity on T2-weighted MRI sequences between the red-red zone of the posterior horn of the medial meniscus and posteromedial capsule.[18] Dephillipo and colleagues[17] described another common finding to be that of a posteromedial tibial bone bruise, which was present in 72% of their patients with ramp lesions.

The vast majority of isolated MCL tears (grades I–III) are initially managed nonoperatively. Conservative treatment emphasizes early rehabilitation, regaining a full range of motion, and progressive weight bearing as tolerated with quadriceps and hamstring strengthening.[19,20] Surgical management of MCL injuries is usually reserved for patients with chronic valgus instability that have failed a trial of nonoperative treatment, or complete (grade III) tears with concomitant multiligament knee injuries.[19,20]

FIGURE 2. Coronal T2-weighted fat-suppressed image reveals a full-thickness proximal MCL tear (grade 3 sprain) leading to mild distal retraction of the torn ligament fibers and surrounding periligamentous soft tissue edema.

Meniscal Pathology

Injuries to the medial and lateral menisci are common at all levels of American football. Bradley et al[21] evaluated 332 elite US college football players at the 2005 NFL Combine and found a history of medial or lateral meniscus injury in 14% of athletes. Lateral meniscal injury was more prevalent in linebackers, whereas medial tears occurred more frequently in tight ends. A more recent study evaluating athletes from the 2009–2015 NFL Combine found that lateral meniscus injuries occurred twice as frequently as medial tears (15.6% vs 7.8%).[22] Tears of the lateral meniscus and acute isolated nondegenerative meniscal tears are associated with ACL injury.

Magnetic resonance imaging is a useful adjunct to the physical examination in the diagnosis of meniscal pathology and allows for the determination of tear location, tear time, and the ability to better predict repairability. Both medial and lateral menisci can be evaluated on fast or conventional spin-echo MRI sequences. However, conventional spin echo has been shown to be significantly more sensitive for meniscal injury (90%) compared with fast spin-echo sequences (80%).[23] On sagittal MR slices, normal menisci have been described as having a low-signal "bow-tie" appearance peripherally on 2 consecutive cuts. Interruption in the congruency of this bowtie appearance should raise concern for meniscal pathology. More medially, sagittal cuts reveal the anterior and posterior horns as 2 similarly sized independent triangles. The variety of tear patterns that may occur can make the characterization of some meniscal tear types challenging for even experienced radiologists and orthopedic surgeons. Morphologies of meniscal tears that have been described include bucket handle, longitudinal, radial, parrot beak, horizontal, and root tears. The location of these tears impacts the likelihood of healing, as the periphery of the meniscus is highly vascularized (red-red zone) and diminishes centrally (red-white zone), with a complete lack of vascularity at the free central edge (white-white zone).

© 2022 Wolters Kluwer Health, Inc. All rights reserved.

Copyright © 2022 Wolters Kluwer Health, Inc. Unauthorized reproduction of this article is prohibited.
This paper can be cited using the date of access and the unique DOI number which can be found in the footnotes.

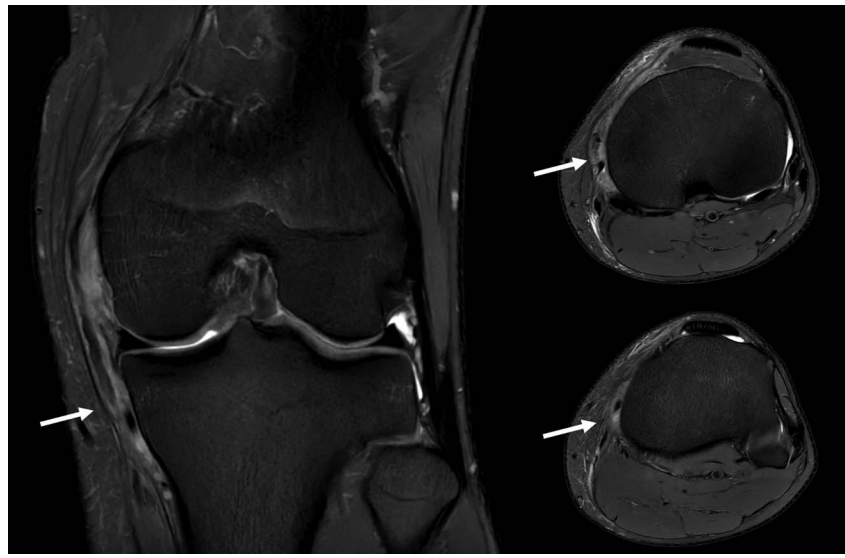

FIGURE 3. A, Coronal proton density fat-suppressed MRI image demonstrates a Stener-like lesion with the MCL-displaced superficial to pes anserinus (white arrow). B and C, Axial proton density-weighted fat-suppressed images of the same patient shows evidence of a Stener lesion: MCL (arrow) is situated superficial to sartorial fascia, gracilis, and semitendinosus tendons (white arrows).

It is important to distinguish true tears from intrasubstance fibrocartilagenous degeneration, which could be the result of repetitive microtrauma or a normal consequence of aging (Fig. 4). If intrasubstance signal fails to reach the femoral or tibial articular surface, then a true meniscal tear cannot be diagnosed. The mischaracterization of intrasubstance degeneration as a true tear has led to a high false-positive rate on MRI, with one study reporting that these false-positive readings tend to occur most often within the posterior horn of the medial meniscus.[24]

Bucket handle tears account for approximately 10% of all meniscal tears and result in significant debilitation (Fig. 5). The displaced bucket handle fragments can become entrapped within the knee joint and cause mechanical locking, warranting surgical intervention. Ververidis et al[25] correlated findings at the time of arthroscopy of bucket handle tears with MRI. They found that nearly 90% of bucket handle tears presented with an absent bow tie sign or a displaced fragment within the intercondylar notch (Fig. 5). Other commonly reported signs such as the double posterior cruciate ligament (PCL) sign or double anterior horn sign occurred less frequently.

Treatment for meniscal tears is dependent on many factors, including the age of the patient, tear size, location, and tear type as well as the degree of osteoarthritis (OA) present (Figs. 6–8). Because the meniscus has a critical role in force dissipation across the tibiofemoral joint, and subtotal meniscectomy has been shown to accelerate OA, there is an increased focus on meniscal preservation.[26,27] In a study of NFL Combine attendees, Smith et al[28] found the prevalence of radiographic knee OA to be 11% in players with a history of meniscal repair and up to 27% in players previously treated with partial meniscectomy. In the setting of prior lateral meniscectomy, full-thickness cartilage loss more commonly develops within the lateral compartment.[29] A recent study by Chahla et al[30] found an inverse relationship between the amount of meniscus remaining and the severity of chondral lesions present in prospective NFL players with previous meniscectomy. Of note, players with previous meniscectomy were found to have significantly worse performance during their playing careers when compared with a matched control group without prior meniscectomy.

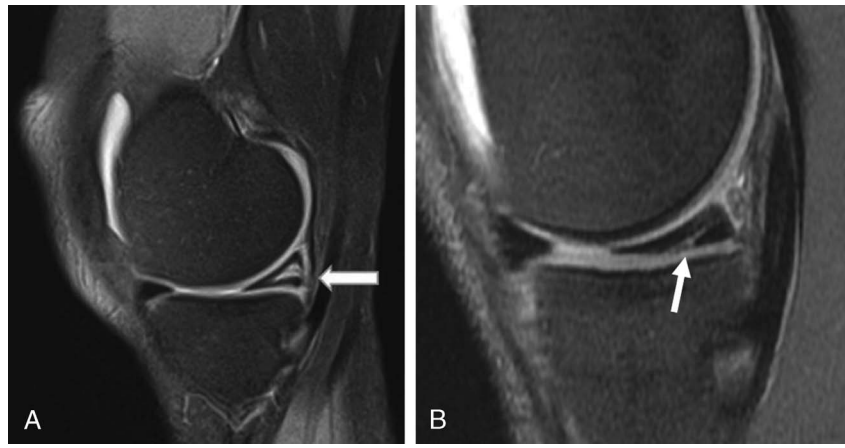

FIGURE 4. Differences between meniscal degeneration and a true meniscal tear. A, Sagittal T2-weighted fat-suppressed cut showing an example of grade 2 meniscal degeneration with increased signal intensity abnormality within the posterior horn of the menial meniscus. B, Separate case with an undersurface nondisplaced posterior horn-meniscal flap tear on a sagittal T2-weighted fat-suppressed image.

© 2022 Wolters Kluwer Health, Inc. All rights reserved.

Copyright © 2022 Wolters Kluwer Health, Inc. Unauthorized reproduction of this article is prohibited.
This paper can be cited using the date of access and the unique DOI number which can be found in the footnotes.

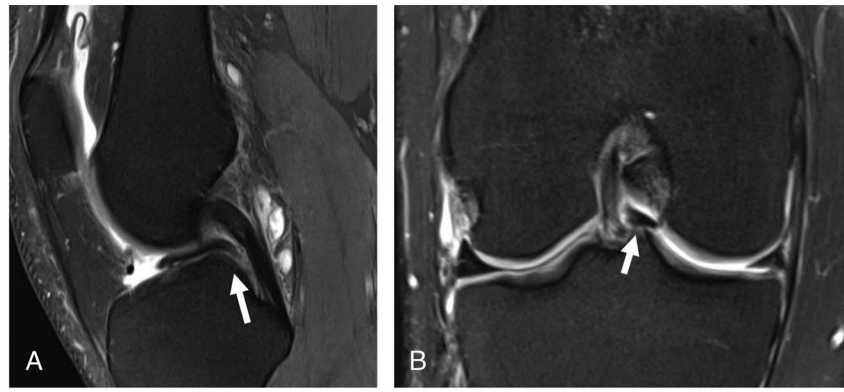

FIGURE 5. Coronal (A) and sagittal (B) T2-weighted fat-suppressed images demonstrate a medial meniscal bucket handle tear with a meniscal fragment displaced into the intercondylar space region. The displaced meniscal fragment is situated inferior to the traversing PCL.

Anterior Cruciate Ligament

Anterior cruciate ligament tear is among the most common knee injury sustained in American football, with one study demonstrating that 10% of NFL Combine attendees reported a history of prior ACL tear.[31] In the general population, the vast majority of these injuries occur with a noncontact mechanism in which a valgus moment combined with either internal or external rotation occurs with the knee in near-full extension.[32] Although previous studies have reported that football players tend to sustain these injuries from direct contact mechanisms, more recent literature analyzing video footage of professional football players suggested that noncontact injuries are more common in this population as well.[33] On MRI, an uninjured ACL will appear as a low signal structure on all sequences and runs in plane with the intercondylar roof on sagittal cuts. T2-weighted images are essential to evaluate ligament integrity, especially in the setting of hemarthrosis, as this can obscure the ligamentous anatomy on T1-weighted images. On the tibial side, the fibers of the ACL begin to fan out, and the subsequent space between the fibers are filled with fat and connective tissue, which will manifest as heterogeneous signal in between the anteromedial and posterolateral bundle. This is a normal finding and should therefore not be confused with a ligamentous tear.[33]

True tears of the ACL are best appreciated on sagittal images (Fig. 9), but coronal and axial images can be important tools to assess for more conspicuous tears not readily seen on sagittal images alone. Acute tears of the ACL are often accompanied by hemorrhage secondary to the disrupted periarticular arterial plexus that supplies the ligament. The resultant hemorrhage and edema will disrupt the continuity of the normal low-signal intensity visualized in healthy ligaments, often making an accurate diagnosis of tear location difficult. The normal anatomic angle of the ACL is important to consider, as a change in the normal ligamentous slope can indicate ACL disruption. On sagittal cuts, complete intrasubstance tears can show an almost vertically oriented sagging femoral segment, whereas the more distal stump will "lie down" or drape inferiorly, no longer respecting the ligament's native anatomic

FIGURE 6. A 23-year-old athlete presents with locking symptoms in his left knee. Coronal T2-weighted fat-suppressed images display a full-thickness radial tear at the posterior root ligament attachment with mild extrusion of the meniscal body into the medial knee gutter.

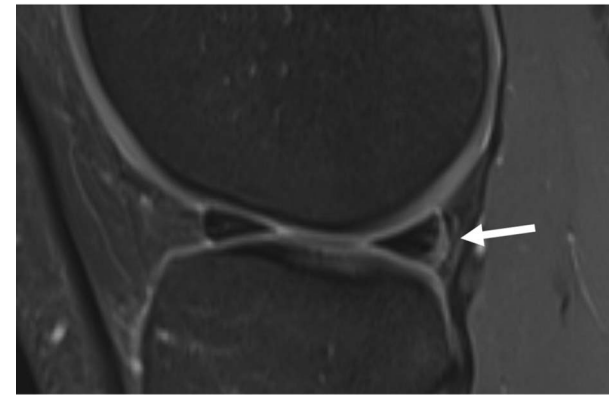

FIGURE 7. Longitudinal vertical tear along the posterior horn of the lateral meniscus (Wrisberg rip) seen on this sagittal T2-weighted fat-suppressed image in an athlete presenting with posterolateral knee pain after 3 weeks of the original injury.

© 2022 Wolters Kluwer Health, Inc. All rights reserved.

Copyright © 2022 Wolters Kluwer Health, Inc. Unauthorized reproduction of this article is prohibited.
This paper can be cited using the date of access and the unique DOI number which can be found in the footnotes.

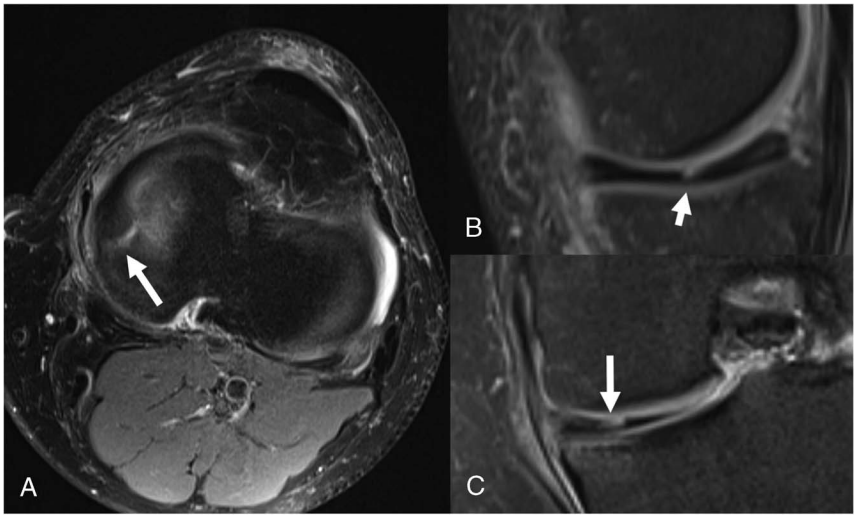

FIGURE 8. A–C, Axial (A), sagittal (B), and coronal (C) T2-weighted fat-suppressed images illustrating a near-complete full-thickness radial tear at the junction of the posterior horn and body of the medial meniscus (white arrow). Note is made of sMCL periligamentous soft tissue swelling consistent with a concurrent type 1 MCL sprain.

angle. Less commonly, tears of the ACL can be associated with bony avulsions, which make inspection of both femoral and tibial attachments important when evaluating for ACL tears. The "empty notch" sign refers to a femoral avulsion fracture where the normal ligamentous insertion is replaced with hemorrhagic fluid. In contrast to the aforementioned findings in acute ACL tears, complete nonvisualization of the ligament in the absence of high-signal intensity fluid and edema is more consistent with a chronic tear. Several other secondary or indirect signs have been reported in the literature to aid in the diagnosis of ACL tears. Gentili and colleagues[34] retrospectively reviewed 89 consecutive knee MRIs, 54 of which had ACL tears confirmed by arthroscopy. Their findings with respect to secondary signs are summarized in Table 1.

The secondary or indirect signs involving osseous abnormalities can also be appreciated on plain radiographs. These indirect signs include deepening of the terminal sulcus of the lateral femoral condyle as well as a Segond fracture. The deep sulcus sign is best appreciated on lateral radiographs and is defined as a deepening of more than 1.5 mm.[35] Segond fractures historically have represented avulsion injuries of the iliotibial (IT) band and lateral joint capsule but have recently been attributed to bony avulsions of the tibial origin of the anterolateral ligament (ALL).[36] With respect to the anterolateral ligamentous anatomy, the ALL originates on the femur either directly or just posterior and proximal to the lateral epicondyle.[37] As the ligament follows an anterior oblique course to the tibia, it forms an attachment to the lateral meniscus just between the anterior horn and the lateral meniscal body.[38] This meniscal attachment, however, is debated as some studies, however, have failed to visualize this meniscal attachment.[39] The distal insertion of the ALL is just posterior and proximal to Gerdy's tubercle. Segond fractures are a specific but not sensitive

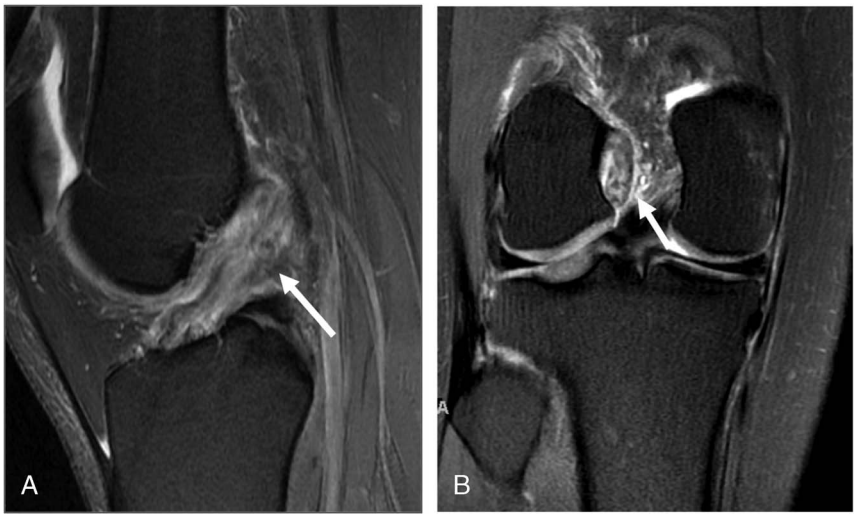

FIGURE 9. Right knee MRI of a 27-year-old football player presenting with an acute injury. Sagittal (A) and coronal (B) T2-weighted fat-suppressed images through the interchondylar space demonstrate evidence of a complete proximal ACL tear. The disruption of the ACL fibers results in a wavy in appearance.

© 2022 Wolters Kluwer Health, Inc. All rights reserved.

Copyright © 2022 Wolters Kluwer Health, Inc. Unauthorized reproduction of this article is prohibited.
This paper can be cited using the date of access and the unique DOI number which can be found in the footnotes.

TABLE 1. Indirect Signs of ACL Tears

Indirect Signs	Sensitivity, %	Specificity, %
Angle between lateral tibial plateau and ACL <45°	90	97
Angle between Bluemsaat's line and ACL >15°	89	100
Bone contusions in lateral compartment	54	100
Position of PCL line	52	91
PCL angle <107°	52	94
PCL bowing ratio >0.39	34	100
Posterior displacement of lateral meniscus >3.5 mm	44	94
Anterior displacement of the tibia >7 mm	41	91
Lateral femoral sulcus deeper than 1.5 mm	19	100

indication of an ACL tear. The incidence of ACL tears with associated Segond fractures has been reported as 7.4% to 15%, with only 1% avulsion fractures presenting without ACL pathology.[40]

Chondral Defects

Articular cartilage defects of the knee are common in football players, with a prevalence as high as 60% in prospective NFL athletes (Fig. 10).[29] Full-thickness lesions account for 27% of these injuries, which occur more frequently in the lateral femoral condyle and in players with a history of meniscectomy.[29] Chondral injuries fall into a wide spectrum of disease and range from asymptomatic to activity limiting and career ending. Provencher and colleagues[40] found that NFL Combine participants with untreated cartilage lesions were drafted later than controls without cartilage lesions and also played fewer games during their first 2 NFL seasons. In the setting of an acute chondral or osteochondral injury, there is often a chondral/osteochondral defect with a donor site, highlighting the importance of assessing for loose chondral or osteochondral fragments. Most articular cartilage defects in this athlete population are asymptomatic and, if symptomatic, often undergo arthroscopic debridement with early return to play. If debridement fails, then the athlete may require osteochondral autograft transplantation (OAT) often followed by return to play within a year.[41]

Although standard knee radiographs are mainly limited to evaluating the joint spaces and for the presence bony abnormalities, they remain an important first step in the diagnosis of chondral injuries. Standard anteroposterior (AP), lateral, patellar skyline or Merchant, and 45-degree posteroanterior flexion (Rosenberg) views may be obtained. On MRI, healthy knee articular cartilage appears as a contiguous trilaminar structure with an intermediate-signal layer interposed between 2 thinner hypointense layers.[42] Fast spin-echo sequences with fat suppression provide excellent differentiation between the suppressed fat in subchondral bone marrow, intermediate-signal articular cartilage, and hyperintense joint fluid. The differentiation within and between soft tissue and bony structures also allows for a more thorough evaluation of associated meniscal and cruciate ligament pathology.[43] Disruption of this normal cartilaginous anatomy resulting in a defect can be categorized into focal or diffuse. Focal defects typically suggest a more acute injury and tend to have sharp, abrupt edges or "shoulders."[44] In contrast, diffuse chondral defects are associated with chronic degenerative changes, such as those seen in players with previous cruciate injury or postmeniscectomy. Diffuse defects of the articular surface in athletes are generally shallower with wide margins and gradually tapering edges. These can be associated with more typical signs of OA such as osteophyte formation and subchondral cysts.[45]

Several grading systems exist for the classification of chondral defects. The most commonly used is the Outerbridge classification, which assesses the severity of cartilage damage when evaluated arthroscopically. Other grading systems have been proposed considering MRI appearance and are summarized in Table 2. The treatment of chondral defects in athletes is complex and continues to evolve as our understanding of the biomechanical properties of cartilage restoration and the roles of orthobiologic therapeutics expand. Surgical decision making should consider the size and location of the lesion, subchondral bony involvement, and a thorough

FIGURE 10. Left knee MRI of a 32—year-old athlete presents with chronic right medial knee pain. Coronal (A) and sagittal (B) T2-weighted fat-suppressed representative images through the medial knee compartment where a moderate-sized osteochondral in situ body is seen with undercutting fluid and underlying subchondral marrow edema constituting findings of osteochondral defect instability.

© 2022 Wolters Kluwer Health, Inc. All rights reserved.

Copyright © 2022 Wolters Kluwer Health, Inc. Unauthorized reproduction of this article is prohibited.
This paper can be cited using the date of access and the unique DOI number which can be found in the footnotes.

TABLE 2. Comparison Between MRI and Arthroscopic Findings in Grading Chondromalacia

Grade	MRI	Arthroscopy
0	Normal cartilage	Normal cartilage
I	Normal contour or slight swelling and signal change	Extensive softening with swelling
II	Superficial fraying; fissuring or ulcerations <50% of cartilage thickness	Surface irregularity less than half cartilage thickness
III	Ulcerations >50% of cartilage thickness	Surface irregularity greater than half cartilage thickness
IV	Full-thickness cartilage defect with exposure of subchondral bone	Ulceration and bony exposure

Adapted from Huysse and Verstraete.[44]

evaluation of associated pathology.[46] When an athlete fails nonoperative management or in the presence of a loose chondral or osteochondral fragment, arthroscopic evaluation of the knee is performed with debridement (chondroplasty) of the symptomatic lesion. The athlete is generally able to return to full participation in team activities within a few weeks of surgery. If the athlete fails a chondroplasty, then other interventions such as an OAT or osteochondral allograft may be considered, although the athlete is generally unable to return to play during that season and may have difficulty returning to the same level of play after recovery. Cell-based cartilage restoration therapies such as matrix-induced autologous chondrocyte implantation and juvenile particulated chondrocyte implantation are seldom used in this population, as the recovery associated with these procedures is longer than osteochondral-based procedures such as OAT and osteochondral allograft.

Posterior Cruciate Ligament

The PCL is the primary ligamentous restraint to posterior translation of the tibia relative to the femur. It is much less frequently injured than the ACL. In a recent study analyzing 2285 athletes participating in the National Collegiate Athletic Association (NCAA) football league, 3% of players had a prior PCL injury, and only 15% of these injuries were managed surgically.[47] Interestingly, the PCL has been found to be significantly more prone to injury when athletes are competing on artificial turf.[48] In football players, the most common mechanism of PCL injury is falling onto a flexed knee with the ipsilateral foot in a plantarflexed position, or a direct tackle to the anterior tibia, mirroring the mechanism of a "dashboard" injury. Grade of PCL injury depends on the amount of posterior tibial translation relative to the femur with the knee flexed to 90 degrees. Grades range from I to III, with grade I injuries producing 1 to 5 mm of posterior tibial translation, grade II producing 6 to 10 mm, and grade III producing >10 mm (Table 3).

Standard radiographs, lateral stress radiographs, and MRI all supplement a thorough history and physical examination in the diagnosis PCL injury. Standard radiographs can be useful in the diagnosis of avulsion fractures, Segond fractures, and joint space changes, as well as in the measurement of mechanical axis alignment.[49] When PCL tears are associated with avulsion fractures, they are more likely to occur at the tibial insertion.[50] Although rare, femoral avulsion fractures, or "peel-off" lesions, have also been described.[51] Several different methods of obtaining PCL stress radiographs have been described in the literature. All strategies involve applying a posterior force to the tibia to quantify the amount of tibial translation with respect to the femur in comparison to the uninjured contralateral side. Complete tears have been associated with 8 to 12 mm of posterior translation, partial tears have been associated with <8 mm, and those with concomitant posterolateral corner (PLC) injury often present with >12 mm.[52–55]

TABLE 3. PCL Grades

Grade	Posterior Tibial Translation at 90° Knee Flexion, mm
I	1–5
II	6–10
III	>10

On MRI, the PCL is best visualized on T2-weighted sagittal images. The uninjured PCL will appear as a slightly curved structure, and unlike the ACL, the PCL exhibits a homogenous hypointensity on all pulse sequences owing to the ligament's unique collagenous composition. Low-signal structures representing the meniscofemoral ligaments may be seen anterior (Humphrey) or posterior (Wrisberg) to the PCL and should be carefully evaluated and not mistaken for loose bodies or torn menisci. Incomplete tears are more common than complete tears and have an abnormal T2 hyperintense signal within the substance of the ligament. Full-thickness tears manifest with signal across the entire width of the ligament indicative of complete fiber discontinuity. Careful evaluation of surrounding structures is also warranted, as isolated PCL injuries are rare. Loughran et al[48] found that athletic injuries reported in the NCAA football league with MRI findings suggestive of a previous PCL injury were frequently accompanied by findings of prior MCL injury (42%), chondral injury (31.8%), and ACL (11.6%) injury. Mair and colleagues[56] found that lateral and medial bone bruises in the setting of PCL tears were associated with MCL and PLC injuries, respectively. Chronic tears of the PCL are often missed on MRI, as the tendency of the ligament is to heal over time and recreate a continuity of nonfunctioning fibers with a similar hypointense appearance as a healthy ligament. DePhillipo and colleagues[55] demonstrated that measurement of posteromedial tibial translation on MRI can be useful in improving diagnostic sensitivity in the setting of chronic PCL tears and PCL graft failures.

POSTEROLATERAL CORNER

The PLC is a complex group of musculotendinous structures that play a crucial role in maintaining stability of the knee. The PLC is composed of several structures including the lateral collateral ligament (LCL), popliteus muscle and tendon, and the popliteofibular ligament (PFL). These structures play an important role in the athlete, as they confer stability in various planes including protecting the knee against varus, posterior tibial translation, and external rotation stresses. Other important components of the PLC include the biceps femoris tendon, IT band, arcuate ligament, and posterior capsule. Posterolateral corner injuries (Fig. 11) may occur secondary to hyperextension, varus, or a combination of hyperextension and external rotation stresses.[57] Isolated PLC injury is rare, as PCL and/or ACL injuries generally occur concomitantly.

Although relatively rare, failure to recognize these injuries can lead to significant residual mechanical instability as well as

© 2022 Wolters Kluwer Health, Inc. All rights reserved.

Copyright © 2022 Wolters Kluwer Health, Inc. Unauthorized reproduction of this article is prohibited.
This paper can be cited using the date of access and the unique DOI number which can be found in the footnotes.

FIGURE 11. Lateral collateral ligament high-grade injury. A, Coronal T2 fat-saturated single images demonstrate full-thickness tearing (grade 3 sprain) of LCL accompanied by extensive ligament fiber discontinuity and surrounding soft tissue hemorrhagic interstitial thickening. B, Corresponding axial T2 fat-saturated image through the femoral condyles demonstrating the extensive high-grade LCL injury.

failure of ACL reconstruction.[44] In a study analyzing PLC injuries in NFL Combine participants, Chahla et al[58] found that 1% of athletes had a history of PLC injury, and those who were treated surgically had significantly greater stability when compared with matched controls.

Standard AP and lateral radiographs are often normal in the setting of isolated PLC injury, but they can be helpful in evaluating for associated pathology. An avulsion fracture of the fibular head, referred to as the "arcuate sign," should raise suspicion for PLC disruption.[58,59] Several authors have also advocated for the use of varus stress radiographs to assess knee stability in players with suspected PLC injuries. LaPrade and colleagues[60] found that asymmetric lateral compartment gapping of with a 4-mm side-to-side difference on stress radiographs is highly associated with grade III PLC tears. This lateral joint space laxity has been referred to as the "drive-through" sign when evaluated arthroscopically.[61]

On MRI, the PLC must be inspected carefully on sagittal, coronal, and axial cuts, as each of these planes highlights different anatomic components of the posterolateral knee. A thorough understanding of normal anatomy is essential, as identification of these injuries is often challenging even for experienced radiologists and orthopedists. Fat-saturated T2-weighted images are best to highlight these injuries. Because isolated PLC injuries are rare, careful evaluation of surrounding structures is warranted, especially the ACL and PCL. Entrapment of the common peroneal nerve has also been reported, most commonly in the setting of biceps femoris avulsions or avulsions of the fibular head.[62]

The LCL should be evaluated carefully, as it serves as the primary restraint to varus stress. The LCL is best appreciated on coronal cuts and will normally appear as a contiguous band of low-signal intensity spanning from its femoral origin posterior and proximal to the lateral epicondyle to its distal attachment on the fibular head. Grade I tears manifest as isolated peritendinous edema without any evidence of fibrous disruption. Intrasubstance signal intensity changes define grade II tears, whereas grade III tears will have complete fiber discontinuity (Fig. 11).

The popliteus musculotendinous complex along with the PFL are best seen on coronal and axial images. Injury to this

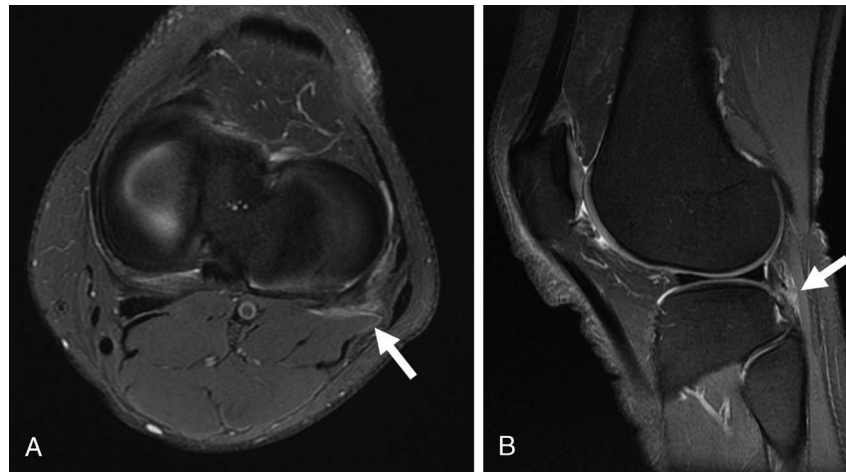

FIGURE 12. Posterolateral corner injury. Axial (A) and sagittal (B) proton density fat-suppressed images showing an example of a high-grade partial thickness tearing of the popliteofibular ligament.

© 2022 Wolters Kluwer Health, Inc. All rights reserved.

Copyright © 2022 Wolters Kluwer Health, Inc. Unauthorized reproduction of this article is prohibited.
This paper can be cited using the date of access and the unique DOI number which can be found in the footnotes.

structure usually occurs within the musculotendinous junction and will manifest as increased signal intensity of the normally hypointense tendinous portion or intermediate-signal muscular portion.[63] The PFL may also be appreciated on coronal and axial images, normally appearing as a hypointense structure spanning from the popliteus musculotendinous junction to the fibular styloid process.[64] Partially torn ligaments (Fig. 12) may demonstrate signal changes within the substance or surrounding the ligament.[65]

The treatment of PLC injuries varies depending on grade of injury and concomitant pathology present. The majority (70%) of NFL Combine attendees with a history of PLC injury were managed surgically.[66] Chahla and colleagues[67] recently conducted an expert consensus on the management of these injuries and concluded that most orthopedic surgeons believe acute PLC injuries should be fixed within 2 to 3 weeks of injury, with reconstruction rather than direct repair being the favored treatment modality. When comparing various multiligament knee injuries, Bakshi et al[68] found that NFL athletes with ACL and MCL tears had a significantly shorter return to play than athletes with combined ACL and PCL or ACL and LCL tears.

POSTEROMEDIAL CORNER

The anatomic structures comprising the posteromedial corner (PMC) are well visualized on MRI. These structures include the posterior horn of the medial meniscus, the posterior oblique ligament (POL), the expansions of the semimembranosus, the posteromedial joint capsule, and the oblique popliteal ligament. Disruption of any of these structure manifests as increased signal on fluid-sensitive MRI sequences (Fig. 13). Special attention has been paid to the POL, as its synergistic relationship with the sMCL confers the knee anteromedial rotatory stability, and it has been shown to be the most frequently torn structure of the PMC.[69] The POL has been described to have 3 arms distally: superficial, central, and capsular.[70] LaPrade et al[71] emphasized the importance of repairing the central arm, which comprises the majority of the ligament's substance. Increased intensity within fluid-sensitive sequences may also be seen within the substance of the semimembranosus or any of its five distal attachments. Increased signal within the insertions of the tendon alone without physical examination findings consistent with instability suggests a diagnosis of an isolated tendinopathy. Management of PMC injuries can present challenges, as these injuries rarely occur in isolation and are often associated with rotational, AP, and valgus instability secondary to multiligamentous injury.[72] As such, in the setting of collateral or cruciate ligament injury, the PMC must be carefully evaluated, as missed PMC tears have been shown to be associated with chronic laxity and graft failure in ACL reconstruction.[73,74]

EXTENSOR MECHANISM

The extensor mechanism of the knee is composed of the quadriceps tendon, the patella, patellar tendon, and patellar retinacula. Boublik and colleagues[75] studied both quadriceps and patellar tendon injuries in NFL players, noting that the most common mechanism of each of these injuries was eccentric overload to a contracting extensor mechanism. The rate of return to play was less favorable in players who sustained quadriceps tendon injuries (50% return to play) compared with players who sustained patellar tendon injuries (80% return to play)[75,76] (Fig. 14).

Ultrasound can serve as an inexpensive yet sensitive modality to evaluate for extensor mechanism disruption. Lewis and colleagues[77] found that knee ultrasound can help predict future extensor mechanism injury in professional football players. They found that upward of 80% of NCAA football players had evidence of prior extensor mechanism pathology on knee ultrasound, which correlated with an increased risk of future extensor mechanism injury in these athletes.[77] Longitudinal ultrasound scanning of the quadriceps tendon can also aid in the differentiation of partial from complete ruptures, with complete ruptures showing a hypoechoic hematoma separating the free distal and proximal ends of torn tendon.[78,79]

Plain radiographs can also aid in the diagnosis of extensor mechanism disruption. On lateral radiographs, quadriceps tendon ruptures can demonstrate significant soft tissue swelling as well as anterior tilting of the superior pole of the patella. The Insall-Savalti ratio compares the patellar tendon length to that of the patellar length on lateral radiographs and is often used to measure patellar height. Normal values are between 0.8 and 1.2. Superior patellar retraction secondary to unopposed pull of the quadriceps tendon in the setting of patellar rupture can increase this ratio leading to a pathologic patella alta.

On MRI, the uninjured quadriceps tendon appears as 3 separate layers as the muscle fibers attach to the superior pole of the patella. From superficial to deep, one can appreciate the fibers of the rectus femoris, medial and lateral vastus medialis, and rectus intermedius, respectively. Partial tears manifest as intrasubstance signal intensities with overlying low-signal structures representing intact tendon. Full-thickness tears of the quadriceps can appear as complete disruption or absence of the tendinous fibers with high-intensity fluid signal changes highlighting the injury (Figs. 14, 15).

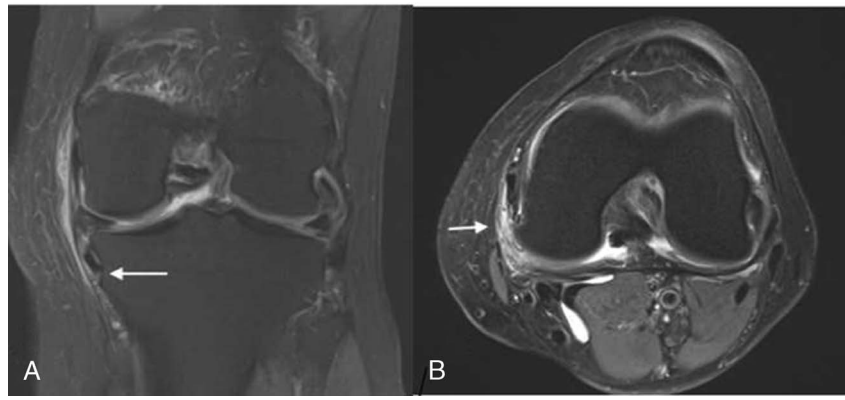

FIGURE 13. Posteromedial corner injury: 25-year-old athlete with posteromedial joint line pain after a subacute injury. Coronal (A) and axial (B) proton density fat-suppressed images showing hyperintensity/edema along the posteromedial joint line–POL consistent with a grade 2 sprain.

© 2022 Wolters Kluwer Health, Inc. All rights reserved.

Copyright © 2022 Wolters Kluwer Health, Inc. Unauthorized reproduction of this article is prohibited.
This paper can be cited using the date of access and the unique DOI number which can be found in the footnotes.

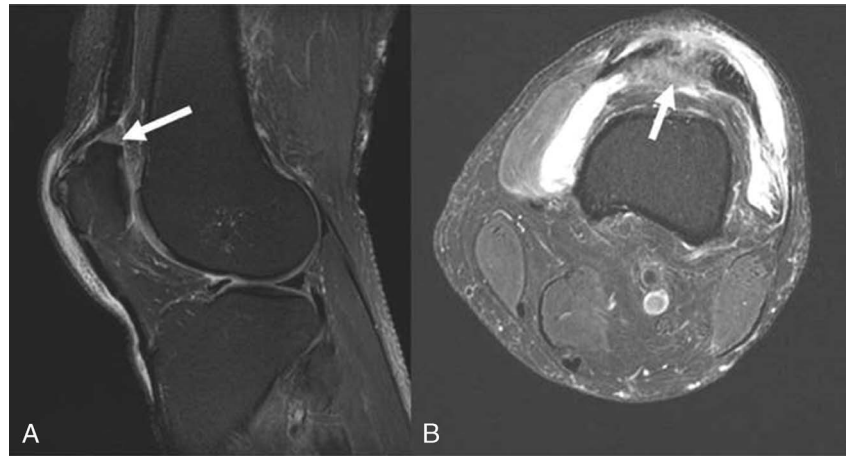

FIGURE 14. White arrows point toward a full-thickness, partial width central tear involving the distal quadriceps tendon insertion with surrounding peritendinous edema and bursitis.

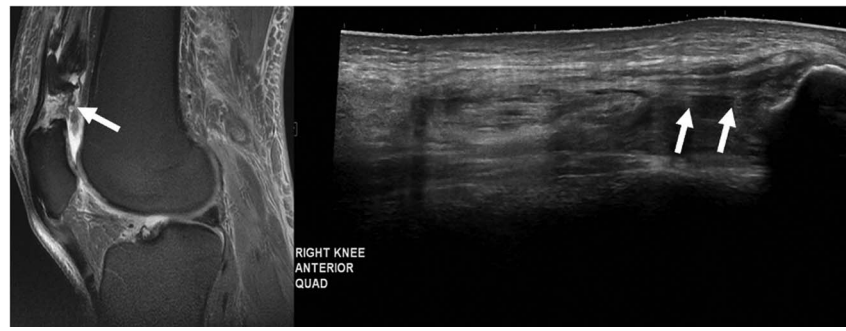

FIGURE 15. Sagittal proton density fat-suppressed demonstrates high-grade partial-thickness undersurface avulsive tear of the distal quadriceps tendon with proximal retraction of the deep torn fibers. Ultrasound longitudinal view on the right demonstrates the large undersurface tear gap with intervening focal hemorrhage.

FIGURE 16. Sagittal proton density fat-suppressed image displaying a full-thickness proximal patellar tendon tear with intervening hemorrhagic thickening and swelling.

 © 2022 Wolters Kluwer Health, Inc. All rights reserved.

Copyright © 2022 Wolters Kluwer Health, Inc. Unauthorized reproduction of this article is prohibited.
This paper can be cited using the date of access and the unique DOI number which can be found in the footnotes.

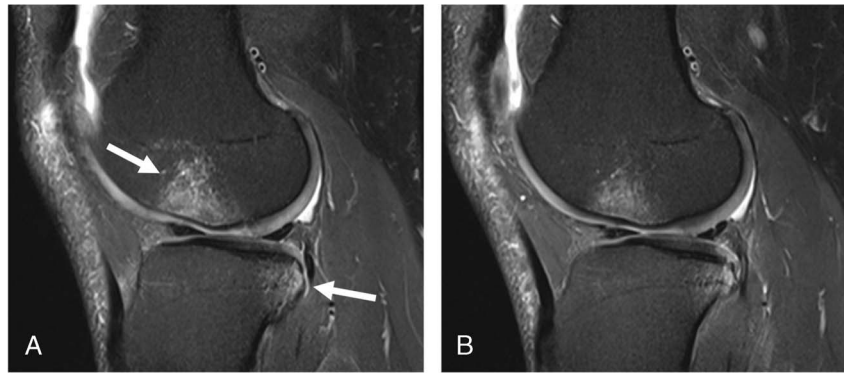

FIGURE 17. Pivot-shift mechanism of injury: valgus stress to flexed and externally rotated knee "kissing contusion pattern" with marrow edema at posterolateral tibial plateau and mid part of lateral femoral condyle seen on these sagittal T2 fat-saturated images.

Similarly, the uninjured patellar tendon appears as a dark signal intensity running from the inferior pole of the patella to its distal attachment on the tibial tubercle. The normal patellar tendon is thinner than the quadriceps tendon. Therefore, a patellar tendon with similar or increased thickness compared with that of the quadriceps tendon suggests tendinopathy. Concomitant injuries are not uncommon: Patellar tendon ruptures in American football players have been reported to have up to a 13% incidence of concomitant ACL tears[75] (Fig. 16).

IT BAND

The IT band is a coalescence of fascial structures in the proximal thigh that extends to insert onto the proximal tibia. Proximally, the fibers originate from the tensor fascia latae, gluteus medius, and gluteus maximus. These fibers conjoin and form an aponeurosis as they coarse distally down the lateral thigh to insert on the lateral supracondylar tubercle of the femur and more distally at Gerdy's tubercle. Iliotibial band friction syndrome is an overuse injury of the knee that is more common in distance runners and cyclists but has also been reported in other competitive sports such as football.[80,81] Although the exact etiology of this syndrome has been debated in the literature, proposed mechanisms include the AP movement that occurs during repetitive flexion-extension of the knee rubbing over the lateral femoral condyle, a compressive syndrome of the highly innervated fat underlying the IT band, and a bursal inflammation.[80,81]

Although the athlete with isolated IT band pathology may not generally require initial radiographic imaging, as accurate diagnosis can often be obtained by history and physical examination alone, a standard radiograph series of the knee can aid the clinician in ruling out other occult causes of lateral knee pain. Because of its inexpensive nature and widespread availability, ultrasound may be a useful imaging modality in the setting of recalcitrant or chronic cases of IT band syndrome (ITBS). Sonographic findings of ITBS can range from a normal fibrous band to varying amounts of band thickening and swelling with discrete pockets of fluid consistent with bursitis.[82] On MRI, coronal T2-weighted images are the most sensitive modality to diagnose ITBS, as these sequences highlight the edema that can be found deep to the IT band at the level of the lateral femoral condyle. Bright-signal intensities can sometimes be appreciated superficial to the IT band, and discrete circumscribed fluid collections can also be seen.[83]

BONE CONTUSION PATTERNS

Osteochondral contusions, commonly referred to as bone bruises, are the edema, hyperemia, and hemorrhage that result from microfractures or injured trabeculae about the injured knee. It is not uncommon to encounter bone contusions when evaluating knee MRIs of athletes who have recently sustained injuries by either direct contact or noncontact mechanisms. Oftentimes these injuries manifest themselves in predictable patterns, which can serve as clues or a "footprint" as to the mechanism and associated

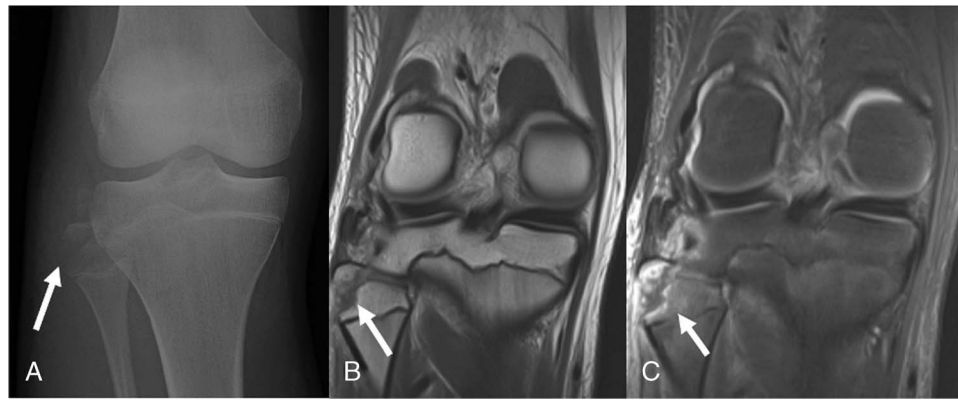

FIGURE 18. Fibular head avulsion fracture. Features on radiograph (A) and coronal T1 fast spin-echo (B) and T2 fast spin-echo with fat saturation (B) are consistent with the arcuate sign, representing an avulsion fracture of the proximal fibula at the site of insertion of the arcuate ligament complex. This injury is commonly associated with cruciate ligament injury (~90% of cases).

© 2022 Wolters Kluwer Health, Inc. All rights reserved.

Copyright © 2022 Wolters Kluwer Health, Inc. Unauthorized reproduction of this article is prohibited.
This paper can be cited using the date of access and the unique DOI number which can be found in the footnotes.

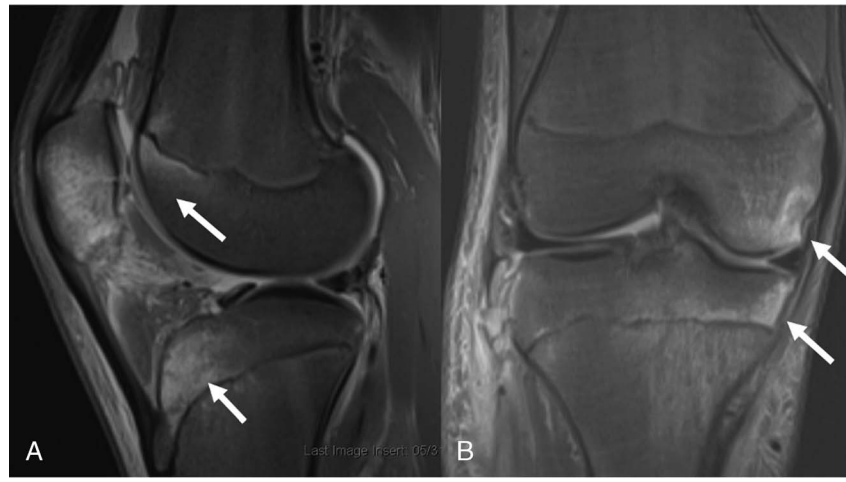

FIGURE 19. Hyperextension injury of the knee experienced during a football game in a high school athlete. Sagittal (A) T2-weighted fast spin-echo MR image with fat saturation shows kissing bone marrow contusions (white arrows) of the anterior aspect of the lateral tibia and femur after a hyperextension injury. Sagittal (B) proton density–weighted spin-echo MR image displays a concurrent valgus stress kissing contusion along the medial knee compartment. Note is made of the marrow edema at the inferior margin of the patella from direct contact with the anterior aspect of the lateral tibial plateau.

injuries these athletes may have sustained. Osteochondral contusions can be appreciated on T1-weighted images as low-intensity heterogeneous signals and on T2-weighted images as high-intensity signals. The classic article by Sanders et al[84] outlined 5 major patterns of osteochondral contusions: pivot shift, dashboard injuries, hyperextension injuries, clip injuries, and lateral patellar dislocations.

The pivot shift is the most common mechanism of the 5 patterns described by Sanders et al. The bone contusion pattern is said to involve the posterior aspect of the lateral tibial plateau and the midportion of the lateral femoral condyle (Fig. 17). When this pattern of bony contusion is noted on the knee MRI of an athlete, disruption of the ACL should be suspected. The PLC should also be closely evaluated in these patients, as it is often an associated injury that can lead to failure of ACL reconstruction if not addressed when present (Fig. 18). In the setting of a PCL injury, characteristic edema may occur along the anterior aspect of the tibia.

Hyperextension injuries cause the anterior aspect of the proximal tibia to contact the anterior femoral condyle resulting in a "kissing contusion" (Fig. 19). This injury pattern can be associated with a variety of soft tissue injuries including PCL, ACL, or meniscal injury. Clip injuries are also common among American football players and are often the result of a direct tackle to the lateral knee producing a primarily valgus force with a secondary flexion component (Fig. 20). The direct blow produces a characteristic pattern of marrow edema on the lateral femoral condyle with a possible associated signal intensity on the medial femoral condyle signaling an avulsion injury at the femoral origin of the MCL.[85]

Lateral patellar dislocations tend to occur secondary to a noncontact twisting injury wherein the femur internally rotates on a fixed tibia, causing the patellar to shift laterally out of the trochlear groove. These injuries may also result from a direct blow to the medial patella with a laterally directed force. The characteristic bone marrow edema pattern can be appreciated on the medial patellar facet and lateral femoral condyle. Associated injuries include the medial patellofemoral ligament and the medial patellar retinaculum.

PATELLAR INSTABILITY

Among athletes, patellar instability results from aberrant lateral displacement (subluxation/dislocation) of the patella with respect to the trochlear groove of the femur. The incidence rate

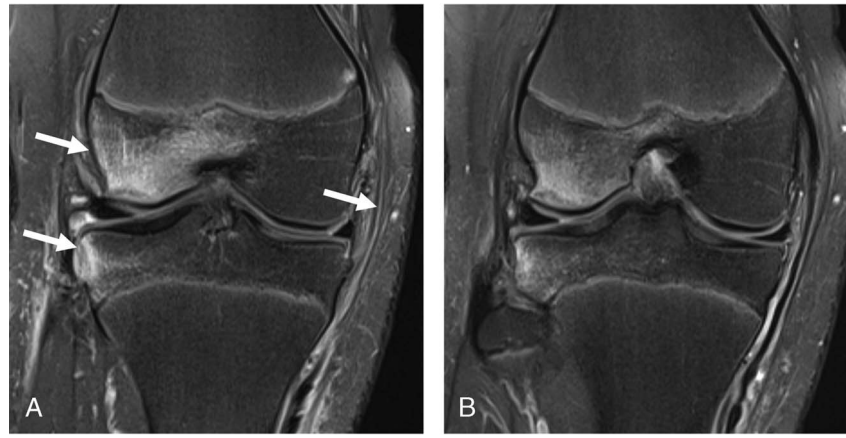

FIGURE 20. Coronal T2 fat-saturated images demonstrating a clip injury: valgus stress to flexed knee contusion pattern. Edema (white arrows) in the lateral femoral condyle and lateral tibial plateau with a low-grade MCL injury.

© 2022 Wolters Kluwer Health, Inc. All rights reserved.

Copyright © 2022 Wolters Kluwer Health, Inc. Unauthorized reproduction of this article is prohibited.
This paper can be cited using the date of access and the unique DOI number which can be found in the footnotes.

has only been reported in younger football players, accounting for approximately 3% of all knee injuries.[86] Female gymnastics followed by male football and wrestling have been documented to have the highest rate of injury, with a nearly 2-fold increase in the risk of recurrent instability that may subsequently lead to chondral injuries and patellofemoral compartment OA.[86] Specifically, the high incidence of patellar dislocations in football is thought to be related to rapid twisting motions and collisions between players or with the ground. Predisposing risk factors include trochlear dysplasia, patella alta, increased tibial tuberosity-trochlear grove distance, or ligament hyperlaxity. Acute dislocation is commonly associated with MCL complex injury, in particular the medial patellofemoral ligament, which provides 50% to 60% soft tissue restraint to lateral displacement.[87]

Patella articular cartilage injury has been reported in up to 95% of patients after first-time dislocations and 96% in recurrent dislocations. The central and medial articular surfaces are the most commonly affected regions, with the inferomedial patella seen as the most commonly injured location. Chondral shearing-type injuries occur as the patella translates over the lateral femoral condyle, secondary to direct contact against the femur in the dislocated position, or during spontaneous reduction. Magnetic resonance imaging findings include the following: (1) reciprocal kissing contusions in the lateral femoral condyle and medial patellar facet with or without associated osteochondral injuries, (2) injury of the medial retinaculum at its patellar/femoral attachments or within its midsubstance, (3) injury to the medial patellofemoral and MCLs, (4) strain of the distal aspect of the vastus medialis obliquus, and (5) patellar tilt and subluxation with joint effusion (Fig. 21).[88] Current rehabilitation strategies aim to regain full range of motion, stabilize patellar tracking, and strengthen the quadriceps. Players are allowed to return to sport when these rehabilitation targets are achieved, and the time frame of return is variable depending on the individual's progress with functional rehabilitation.

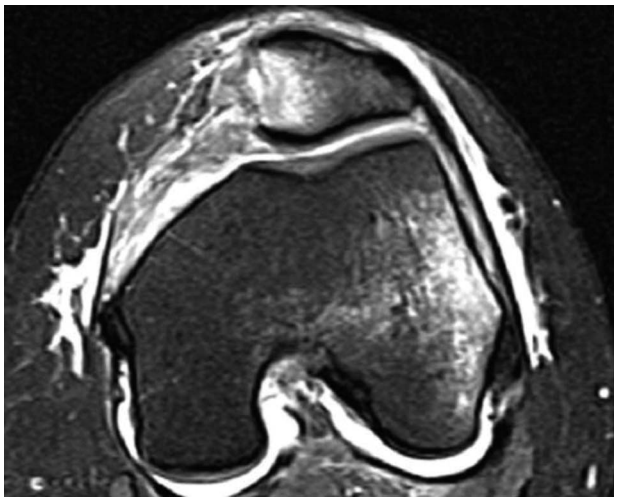

FIGURE 21. Axial proton-density fat-saturated MR image through the midportion of the trochlea exhibiting "kissing" edema contusion at the inferomedial patella and lateral femoral condyle. Note the extensive-high grade diffuse medial retinacular injury with minimal avulsion at the patella attachment. Accompanying evidence of a shallow trochlea, predisposing to lateral patellar subluxation/dislocation.

CONCLUSIONS

Treatment of knee injuries among high-performance football players requires knowledge of the complex anatomy and an understanding of injury mechanisms to accurately diagnose the underlying pathology. Imaging, especially MRI, plays a crucial role in the detection of injuries within and surrounding the knee including osseous, ligamentous, tendinous, and meniscal structures. A thorough understanding of these pathological findings as assessed by imaging is critical in helping to formulate a treatment plan for these athletes.

REFERENCES

1. Dvorak J, Junge A. Football injuries and physical symptoms. A review of the literature. *Am J Sports Med*. 2000;28(suppl 5):S3–S9. doi:10.1177/28.suppl_5.s-3. PMID: 11032101.
2. Hootman JM, Dick R, Agel J. Epidemiology of collegiate injuries for 15 sports: summary and recommendations for injury prevention initiatives. *J Athl Train*. 2007;42:311–319.
3. Shankar PR, Fields SK, Collins CL, et al. Epidemiology of high school and collegiate football injuries in the United States, 2005–2006. *Am J Sports Med*. 2007;35:1295–1303.
4. Clifton DR, Onate JA, Schussler E, et al. Epidemiology of knee sprains in youth, high school, and collegiate American football players. *J Athl Train*. 2017;52:464–473.
5. Feeley BT, Kennelly S, Barnes RP, et al. Epidemiology of National Football League training camp injuries from 1998 to 2007. *Am J Sports Med*. 2008;36:1597–1603.
6. Rasenberg EI, Lemmens JA, van Kampen A, et al. Grading medial collateral ligament injury: comparison of MR imaging and instrumented valgus-varus laxity test-device. A prospective double-blind patient study. *Eur J Radiol*. 1995;21:18–24.
7. Schein A, Matcuk G, Patel D, et al. Structure and function, injury, pathology, and treatment of the medial collateral ligament of the knee. *Emerg Radiol*. 2012;19:489–498.
8. Yao L, Dungan D, Seeger LL. MR imaging of tibial collateral ligament injury: comparison with clinical examination. *Skeletal Radiol*. 1994;23:521–524.
9. Mirowitz SA, Shu HH. MR imaging evaluation of knee collateral ligaments and related injuries: comparison of T1-weighted, T2-weighted, and fat-saturated T2-weighted sequences—correlation with clinical findings. *J Magn Reson Imaging*. 1994;4:725–732.
10. Farshad-Amacker NA, Potter HG. MRI of knee ligament injury and reconstruction. *J Magn Reson Imaging*. 2013;38:757–773.
11. Logan CA, Murphy CP, Sanchez A, et al. Medial collateral ligament injuries identified at the National Football League Scouting Combine: assessment of epidemiological characteristics, imaging findings, and initial career performance. *Orthop J Sports Med*. 2018;6:2325967118787182.
12. Taketomi S, Uchiyama E, Nakagawa T, et al. Clinical features and injury patterns of medial collateral ligament tibial side avulsions: "wave sign" on magnetic resonance imaging is essential for diagnosis. *Knee*. 2014;21:1151–1155.
13. LaPrade RF, Bernhardson AS, Griffith CJ, et al. Correlation of valgus stress radiographs with medial knee ligament injuries: an in vitro biomechanical study. *Am J Sports Med*. 2010;38:330–338.
14. Strobel MJ. *Manual of Arthroscopic Surgery*. New York, NY: Springer; 1988.
15. Liu X, Feng H, Zhang H, et al. Arthroscopic prevalence of ramp lesion in 868 patients with anterior cruciate ligament injury. *Am J Sports Med*. 2011;39:832–837.
16. Sonnery-Cottet B, Conteduca J, Thaunat M, et al. Hidden lesions of the posterior horn of the medial meniscus: a systematic arthroscopic exploration of the concealed portion of the knee. *Am J Sports Med*. 2014;42:921–926.

© 2022 Wolters Kluwer Health, Inc. All rights reserved.

Copyright © 2022 Wolters Kluwer Health, Inc. Unauthorized reproduction of this article is prohibited.
This paper can be cited using the date of access and the unique DOI number which can be found in the footnotes.

17. DePhillipo NN, Cinque ME, Chahla J, et al. Incidence and detection of meniscal ramp lesions on magnetic resonance imaging in patients with anterior cruciate ligament reconstruction. *Am J Sports Med*. 2017;45: 2233–2237.
18. Greif DN, Baraga MG, Rizzo MG, et al. MRI appearance of the different meniscal ramp lesion types, with clinical and arthroscopic correlation. *Skeletal Radiol*. 2020;49:677–689.
19. Miyamoto RG, Bosco JA, Sherman OH. Treatment of medial collateral ligament injuries. *J Am Acad Orthop Surg*. 2009;17:152–161.
20. Azar FM. Evaluation and treatment of chronic medial collateral ligament injuries of the knee. *Sports Med Arthrosc Rev*. 2006;14:84–90.
21. Bradley J, Honkamp NJ, Jost P, et al. Incidence and variance of knee injuries in elite college football players. *Am J Orthop (Belle Mead NJ)*. 2008;37:310–314.
22. Beaulieu-Jones BR, Rossy WH, Sanchez G, et al. Epidemiology of injuries identified at the NFL Scouting Combine and their impact on performance in the National Football League: evaluation of 2203 athletes from 2009 to 2015. *Orthop J Sports Med*. 2017;5:2325967117708744.
23. Helms CA. The meniscus: recent advances in MR imaging of the knee. *Am J Roentgenol*. 2002;179:1115–1122.
24. De Smet AA, Nathan DH, Graf BK, et al. Clinical and MRI findings associated with false-positive knee MR diagnoses of medial meniscal tears. *Am J Roentgenol*. 2008;191:93–99.
25. Ververidis AN, Verettas DA, Kazakos KJ, et al. Meniscal bucket handle tears: a retrospective study of arthroscopy and the relation to MRI. *Knee Surg Sports Traumatol Arthrosc*. 2006;14:343–349.
26. Abram SGF, Judge A, Beard DJ, et al. Long-term rates of knee arthroplasty in a cohort of 834 393 patients with a history of arthroscopic partial meniscectomy. *Bone Joint J*. 2019;101-B:1071–1080.
27. Laible C, Stein DA, Kiridly DN. Meniscal repair. *J Am Acad Orthop Surg*. 2013;21:204–213.
28. Smith MV, Nepple JJ, Wright RW, et al. Knee osteoarthritis is associated with previous meniscus and anterior cruciate ligament surgery among elite college American football athletes. *Sports Health*. 2017;9:247–251.
29. Nepple JJ, Wright RW, Matava MJ, et al. Full-thickness knee articular cartilage defects in National Football League Combine athletes undergoing magnetic resonance imaging: prevalence, location, and association with previous surgery. *Art Ther*. 2012;28:798–806.
30. Chahla J, Cinque ME, Godin JA. Meniscectomy and resultant articular cartilage lesions of the knee among prospective national football league players: an imaging and performance analysis. *Am J Sports Med*. 2018;46: 200–207.
31. Rothenberg P, Grau L, Kaplan L, et al. Knee injuries in American football: an epidemiological review. *Am J Orthop (Belle Mead NJ)*. 2016;45:368–373.
32. Olsen OE, Myklebust G, Engebretsen L, et al. Injury mechanisms for anterior cruciate ligament injuries in team handball: a systematic video analysis. *Am J Sports Med*. 2004;32:1002–1012.
33. Johnston JT, Mandelbaum BR, Schub D, et al. Video analysis of anterior cruciate ligament tears in professional American football athletes. *Am J Sports Med*. 2018;46:862–868.
34. Gentili A, Seeger LL, Yao L, et al. Anterior cruciate ligament tear: indirect signs at MR imaging. *Radiology*. 1994;193:835–840.
35. Shaikh H, Herbst E, Rahnemai-Azar AA, et al. The Segond fracture is an avulsion of the anterolateral complex. *Am J Sports Med*. 2017;45: 2247–2252.
36. Daggett M, Ockuly AC, Cullen M. Femoral origin of the anterolateral ligament: an anatomic analysis. *Arthroscopy*. 2016;32:835–841.
37. Helito CP, Bonadio MB, Soares TQ. The meniscal insertion of the knee anterolateral ligament. *Surg Radiol Anat*. 2016;38:223–228.
38. Taneja AK, Miranda FC, Braga CA, et al. MRI features of the anterolateral ligament of the knee. *Skeletal Radiol*. 2015;44:403–410.
39. Slagstad I, Parkar AP, Strand T, et al. Incidence and prognostic significance of the Segond fracture in patients undergoing anterior cruciate ligament reconstruction. *Am J Sports Med*. 2020;48:1063–1068.
40. Provencher MT, Chahla J, Cinque ME, et al. Symptomatic Focal Knee Chondral Injuries in National Football League Combine Players Are Associated With Poorer Performance and Less Volume of Play. *Arthroscopy*. 2018;34:671–677.
41. Scillia AJ, Aune KT, Andrachuk JS, et al. Return to play after chondroplasty of the knee in National Football League athletes. *Am J Sports Med*. 2015;43:663–668.
42. Forney M, Subhas N, Donley B, et al. MR imaging of the articular cartilage of the knee and ankle. *Magn Reson Imaging Clin N Am*. 2011;19:379–405.
43. Potter HG, Foo LF. Magnetic resonance imaging of articular cartilage: trauma, degeneration, and repair. *Am J Sports Med*. 2006;34:661–677.
44. Morrison WB, Major N. The knee. *Top Magn Reson Imaging*. 2015;24: 193–203.
45. Huysse W, Verstraete K. Internal derangement of the knee: cartilage and osteochondral injuries. In: Pope T, Bloem H, Beltran J, et al, eds. *Musculoskeletal Imaging*. Philadelphia, PA: Elsevier; 2015:29-1–29-14.e3.
46. Alford JW, Cole BJ. Cartilage restoration, part 2: techniques, outcomes, and future directions. *Am J Sports Med*. 2005;33:443–460.
47. Logan CA, Beaulieu-Jones BR, Sanchez G, et al. Posterior cruciate ligament injuries of the knee at the National Football League Combine: an imaging and epidemiology study. *Art Ther*. 2018;34:681–686.
48. Loughran GJ, Vulpis CT, Murphy JP, et al. Incidence of knee injuries on artificial turf versus natural grass in National Collegiate Athletic Association American football: 2004–2005 through 2013–2014 seasons. *Am J Sports Med*. 2019;47:1294–1301.
49. LaPrade CM, Civitarese DM, Rasmussen MT, et al. Emerging updates on the posterior cruciate ligament: a review of the current literature. *Am J Sports Med*. 2015;43:3077–3092.
50. Hooper PO III, Silko C, Malcolm TL, et al. Management of posterior cruciate ligament tibial avulsion injuries: a systematic review. *Am J Sports Med*. 2018;46:734–742.
51. Ross G, Driscoll J, McDevitt E, et al. Arthroscopic posterior cruciate ligament repair for acute femoral "peel off" tears. *Arthroscopy*. 2003;19:431–435.
52. Jung TM, Reinhardt C, Scheffler SU, et al. Stress radiography to measure posterior cruciate ligament insufficiency: a comparison of five different techniques. *Knee Surg Sports Traumatol Arthrosc*. 2006;14:1116–1121.
53. Schulz MS, Steenlage ES, Russe K, et al. Distribution of posterior tibial displacement in knees with posterior cruciate ligament tears. *J Bone Joint Surg Am*. 2007;89:332–338.
54. Jackman T, LaPrade RF, Pontinen T, et al. Intraobserver and interobserver reliability of the kneeling technique of stress radiography for the evaluation of posterior knee laxity. *Am J Sports Med*. 2008;36:1571–1576.
55. DePhillipo NN, Cinque ME, Godin JA, et al. Posterior tibial translation measurements on magnetic resonance imaging improve diagnostic sensitivity for chronic posterior cruciate ligament injuries and graft tears. *Am J Sports Med*. 2018;46:341–347.
56. Mair SD, Schlegel TF, Gill TJ, et al. Incidence and location of bone bruises after acute posterior cruciate ligament injury. *Am J Sports Med*. 2004;32: 1681–1687.
57. Nannaparaju M, Mortada S, Wiik A, et al. Posterolateral corner injuries: epidemiology, anatomy, biomechanics and diagnosis. *Injury*. 2018;49: 1024–1031.
58. Chahla J, Kennedy NI, Cinque ME, et al. Posterolateral corner injuries of the knee at the National Football League Combine: an imaging and outcomes analysis. *Arthroscopy*. 2018;34:687–692.
59. Shindell R, Walsh WM, Connolly JF. Avulsion fracture of the fibula: the 'arcuate sign' of posterolateral knee instability. *Nebr Med J*. 1984;69: 369–371.

© 2022 Wolters Kluwer Health, Inc. All rights reserved.

Copyright © 2022 Wolters Kluwer Health, Inc. Unauthorized reproduction of this article is prohibited.
This paper can be cited using the date of access and the unique DOI number which can be found in the footnotes.

60. LaPrade RF, Heikes C, Bakker AJ, et al. The reproducibility and repeatability of varus stress radiographs in the assessment of isolated fibular collateral ligament and grade-III posterolateral knee injuries. An in vitro biomechanical study. *J Bone Joint Surg Am*. 2008;90:2069–2076.
61. LaPrade RF. Arthroscopic evaluation of the lateral compartment of knees with grade 3 posterolateral knee complex injuries. *Am J Sports Med*. 1997; 25:596–602.
62. Bottomley N, Williams A, Birch R, et al. Displacement of the common peroneal nerve in posterolateral corner injuries of the knee. *J Bone Joint Surg Br*. 2005;87:1225–1226.
63. Vinson EN, Major NM, Helms CA. The posterolateral corner of the knee. *AJR Am J Roentgenol*. 2008;190:449–458.
64. Pacholke DA, Helms CA. MRI of the posterolateral corner injury: a concise review. *J Magn Reson Imaging*. 2007;26:250–255.
65. Rosas HG. Unraveling the posterolateral corner of the knee. *Radiographics*. 2016;36:1776–1791.
66. Bushnell BD, Bitting SS, Crain JM, et al. Treatment of magnetic resonance imaging documented isolated grade III lateral collateral ligament injuries in National Football League athletes. *Am J Sports Med*. 2010;38:86–91.
67. Chahla J, Murray IR, Robinson J, et al. Posterolateral corner of the knee: an expert consensus statement on diagnosis, classification, treatment, and rehabilitation. *Knee Surg Sports Traumatol Arthrosc*. 2019;27:2520–2529.
68. Bakshi NK, Khan M, Lee S, et al. Return to play after multiligament knee injuries in National Football League athletes. *Sports Health*. 2018;10: 495–499.
69. Robinson JR, Sanchez-Ballester J, Bull AM, et al. The posteromedial corner revisited. An anatomical description of the passive restraining structures of the medial aspect of the human knee. *J Bone Joint Surg Br*. 2004;86:674–681. doi:10.1302/0301620x.86b5.14853. PMID: 15274262.
70. Dold AP, Swensen S, Strauss E, et al. The posteromedial corner of the knee: anatomy, pathology, and management strategies. *J Am Acad Orthop Surg*. 2017;25:752–761.
71. LaPrade RF, Wijdicks CA. Surgical technique: development of an anatomic medial knee reconstruction. *Clin Orthop Relat Res*. 2012;470:806–814.
72. Chahal J, Al-Taki M, Pearce D, et al. Injury patterns to the posteromedial corner of the knee in high-grade multiligament knee injuries: a MRI study. *Knee Surg Sports Traumatol Arthrosc*. 2010;18:1098–1104.
73. Robinson JR, Bull AM, Thomas RR, et al. The role of the medial collateral ligament and posteromedial capsule in controlling knee laxity. *Am J Sports Med*. 2006;34:1815–1823.
74. Sims WF, Jacobson KE. The posteromedial corner of the knee: medial-sided injury patterns revisited. *Am J Sports Med*. 2004;32:337–345.
75. Boublik M, Schlegel T, Koonce R, et al. Patellar tendon ruptures in National Football League players. *Am J Sports Med*. 2011;39:2436–2440.
76. Rasul AT Jr., Fischer DA. Primary repair of quadriceps tendon ruptures. Results of treatment. *Clin Orthop Relat Res*. 1993;205–207.
77. Lewis RA, Cook CR, Smith PA, et al. Knee ultrasonography to determine risk for noncontact injuries in collegiate American football players. *J Knee Surg*. 2020;33:666–672.
78. Ilan DI, Tejwani N, Keschner M, et al. Quadriceps tendon rupture. *J Am Acad Orthop Surg*. 2003;11:192–200.
79. Bianchi S, Zwass A, Abdelwahab IF, et al. Diagnosis of tears of the quadriceps tendon of the knee: value of sonography. *AJR Am J Roentgenol*. 1994;162:1137–1140.
80. Martens M, Libbrecht P, Burssens A. Surgical treatment of the iliotibial band friction syndrome. *Am J Sports Med*. 1989;17:651–654.
81. Orchard JW, Fricker PA, Abud AT, et al. Biomechanics of iliotibial band friction syndrome in runners. *Am J Sports Med*. 1996; 24:375–379.
82. Jiménez Díaz F, Gitto S, Sconfienza LM, et al. Ultrasound of iliotibial band syndrome. *J Ultrasound*. 2020;23:379–385.
83. Muhle C, Ahn JM, Yeh L, et al. Iliotibial band friction syndrome: MR imaging findings in 16 patients and MR arthrographic study of six cadaveric knees. *Radiology*. 1999;212:103–110.
84. Sanders TG, Medynski MA, Feller JF, et al. Bone contusion patterns of the knee at MR imaging: footprint of the mechanism of injury. *Radiographics*. 2000;20 Spec No:S135–S151.
85. Schweitzer ME, Tran D, Deely DM, et al. Medial collateral ligament injuries: evaluation of multiple signs, prevalence and location of associated bone bruises, and assessment with MR imaging. *Radiology*. 1995;194: 825–829.
86. Mitchell J, Magnussen RA, Collins CL, et al. Epidemiology of patellofemoral instability injuries among high school athletes in the United States. *Am J Sports Med*. 2015;43:1676–1682.
87. Saggin PR, Saggin JI, Dejour D. Imaging in patellofemoral instability: an abnormality-based approach. *Sports Med Arthrosc Rev*. 2012;20: 145–151.
88. Mason JJ, Leszko F, Johnson T, et al. Patellofemoral joint forces. *J Biomech*. 2008;41:2337–2348.

© 2022 Wolters Kluwer Health, Inc. All rights reserved.

Copyright © 2022 Wolters Kluwer Health, Inc. Unauthorized reproduction of this article is prohibited.
This paper can be cited using the date of access and the unique DOI number which can be found in the footnotes.